

Davis-Thompson Foundation Photo Contest

Have your prized image featured on the cover page of the monthly newsletter!

The Davis-Thomson Foundation invites you to submit digital gross, microscopic, or ultrastructural images depicting a lesion, to be featured on the front page of the monthly newsletter. Each month a new image will take pride of place in the issue.

Worried about image copyrights? Have no fear, the foundation does not claim copyright for any material published by us.

Submission information:

- Submission deadline: The **10th** of each month to be considered for the upcoming issue
- **Send your image by e-mail to:**
 - Dr. Kate Watson and Dr. Donald McGavin: images@davisthompsonfoundation.org

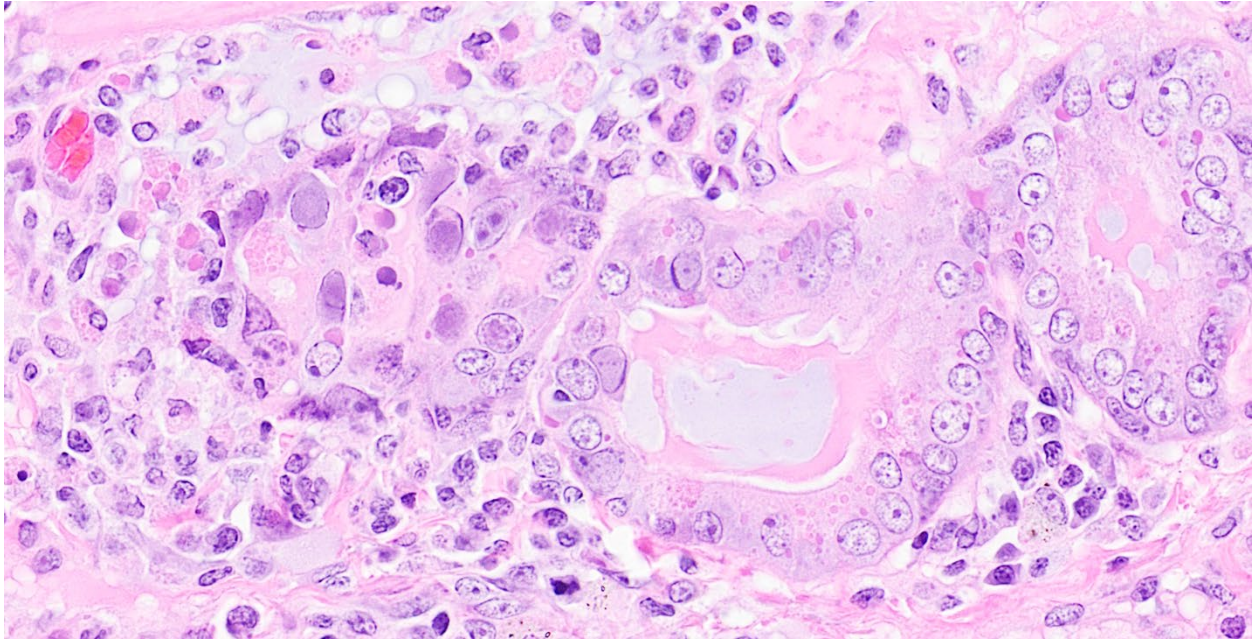
Figure Requirements (see examples below):

- Do not exceed maximum file size of 5 MB.
- Width of the image should be 6.8 inches.
- Acceptable formats are TIFF and JPEG.
 - **Minimum acceptable resolution is 300 pixels/inch** (120 pixels/cm) for half-tones (i.e., photographs, histology images).
 - We recommend saving your images as TIFF files with LZW compression. LZW compression will reduce file size (sometimes dramatically) without affecting quality.
 - When you are saving a file such as a TIFF from any package such as Photoshop, you are given the option of compressing the file. LZW compression will speed up the upload and download times and will not affect your image in a negative way.

Figure Legend (attach as a word document separated from the image file):

- Name/names of contributors and their affiliated institutions.
- Brief (no longer than 2 sentence) description of the lesion including:
 - Signalment
 - Diagnosis
 - Any other pertinent information you want to share

Example(s):



An adult female striped skunk with canine distemper virus (eosinophilic, intracytoplasmic inclusions) and adenovirus (basophilic, intranuclear inclusions) in the submucosal glands of the tracheobronchial airways.

Contributor: Katherine D. Watson

Contributor institutional affiliation: California Animal Health and Food Safety Laboratory, University of California-Davis, Davis, CA

File size: 4.66 MB, 6.8 inches wide

File type: .tif (saved in LZW compression format)

Image resolution: 300 pixels/inch



Direct examination of hair from an alopecic, 1-year-old black bear with ectothrix dermatophyte spores and hyphae.

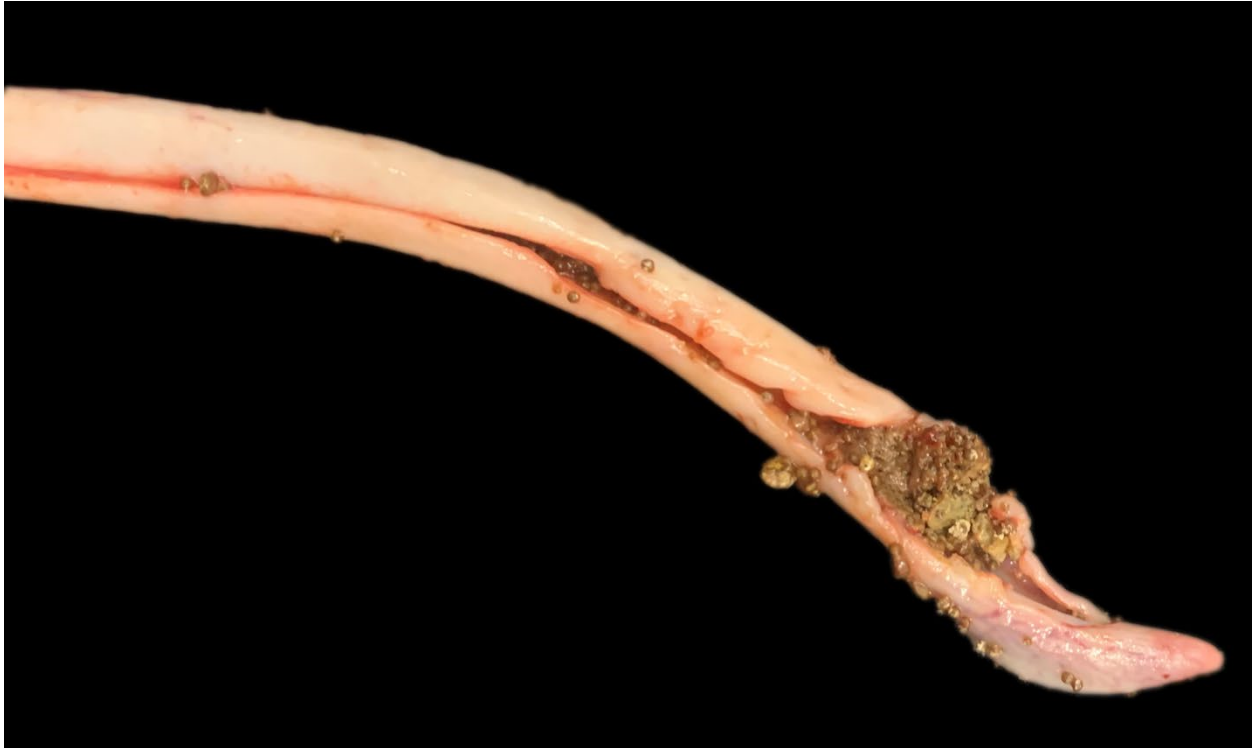Contributor: Omar A. Gonzales-Viera and Katherine D. Watson

Contributor institutional affiliation: California Animal Health and Food Safety Laboratory, University of California-Davis, Davis, CA

File size: 1.58 MB, 6.8 inches wide

File type: .tif (saved in LZW compression format)

Image resolution: 300 pixels/inch



Obstructive penile urethral urolithiasis in a 10-year-old pot-bellied pig with calcium phosphate carbonate stones.

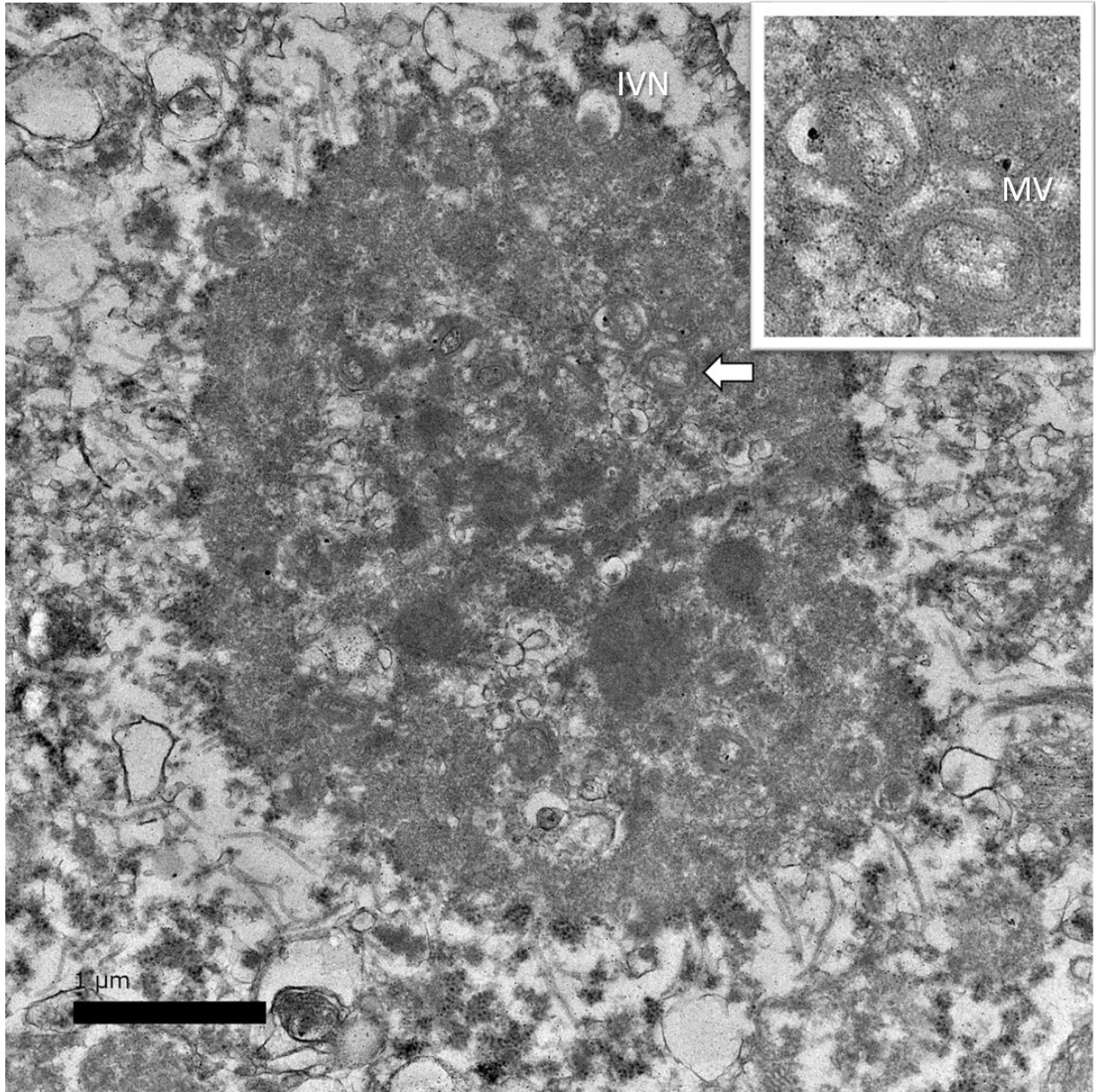
Contributor: Katherine D. Watson

Contributor institutional affiliation: California Animal Health and Food Safety Laboratory, University of California-Davis, Davis, CA

File size: 620 kb, 6.8 inches wide

File type: .tif (saved in LZW compression format)

Image resolution: 300 pixels/inch



Electron micrograph of an intracytoplasmic inclusion in the liver of a 2-year-old, male domesticated rabbit demonstrating a poxvirus factory (previously called Guarnieri bodies) with immature virions (IV), immature virions with nucleoid (IVN), mature virions (MV), and wrapped virions (WV; see inset).

Contributor: Anibal G. Armien and Katherine D. Watson

Contributor institutional affiliation: California Animal Health and Food Safety Laboratory, University of California-Davis, Davis, CA

File size: 1.95 MB, 6.8 inches wide

File type: .tif

Image resolution: 300 pixels/inch